

Brain & Mind Consultation, Diagnostic Centre.

Dhap 8 tola Mosque Road (North Side), Kakolee Lane, Dhap, Rangpur
Mob: 01865-771717

Patient Copy

Name : MD.IMRAN
Age : 38 YRS

SL No. : B & M-25
ID No. : 04063/02-2024
Date : 10-Feb-24

Refd.By : Asst.Prof.Dr.Abul Kalam Azad MBBS.BCS.FCPS(Medi)

| SL. | Advice | Amount |
|---|-------------------------|------------------------|
| 1 | Chest P/A X Ray Digital | 600 |
| * অনিবার্য কারণে পরীক্ষা নিরীক্ষা ও রিপোর্ট ডেলিভারি বিলম্ব হতে পারে। | | Gross Total 600 |
| * রিপোর্ট ডেলিভারির সময় এই মেমো অবশ্যই প্রদর্শন করতে হবে। | | Add. Charge 0 |
| Delivery DT: | 10-Feb-24 | |
| Delivery TM: | | Net Total 600 |
| Posted By | Sumon 01 | |
| 10-Feb-24 5:33:39 PM | Due | Due 600 |
| Powered By : <u>UniCom Computers, Rangpur.</u> | | |

PAID

Sum
10.2.24



রংপুর হেলথ সিটি স্পেশালাইজড হসপিটাল এন্ড ডায়াগনোস্টিক সেন্টার
Rangpur Health City Specialized Hospital & Diagnostic Center

কাকলী লেন, আটতলা মসজিদের উত্তর পাশে। ষাণ্ড রংপুর। হেল্প লাইনঃ ০১৭১৭-৩০২০০২

Patient Copy

Patient: MD IMRAN (ID 20240210-016) Sex : Male Age : 38 years

Receipt No - 20240210-0016 Date 2024-02-10 05:26:42 TR : 8193

Address : RANGPUR Mobile : 01761730071

Ref By : Assistant Prof. Dr. Md. Abul Kafam Azad (Tutul) MBBS, FCPS (Medicine).



| SI Item | Room | Price |
|------------------------------|-----------------------|------------|
| 1 RBS with CUS | 205 | 200.00 Tk |
| 2 Serum Creatinine | 205 | 350.00 Tk |
| 3 USG Of Whole Abdomen (W/A) | 102 | 1000.00 Tk |
| 4 CBC | 205 | 500.00 Tk |
| 5 Urine R/M/E | | 300.00 Tk |
| 6 Troponin- I | 205 | 1000.00 Tk |
| | Sub Total Tk. | 3350 |
| | - Discount Tk. | 1250 |
| | Net Payable Tk. | 2100 |
| | Total Paid Amount Tk. | 2100 |
| | Due Tk. | 0 |

PAID

বি দ্রঃ ৩০ দিনের মধ্যে রিপোর্ট টি নেওয়ার জন্য অনুরোধ করা হল। রিপোর্ট ডেলিভেরির সময় এই মেমো অবশ্যই আনতে হবে।

Printed By User, Printing Time 2024-02-10 05:26:43

Hema Digital Diagnostic Center

Dhap City Bazar, Cant Road, Rangpur Sadar, Rangpur

| | | | |
|------------------|---|----------------------------|---------------|
| Name : | Md Imran | SL No : HDDC-52 | |
| Age : | 38 Year | Date : 10-Feb-24 | |
| Refd By : | Assist. Prof. Dr. Md. Abul Kalam Azad (Tutul) MBBS; FCPS (Med) | Time: 2/10/2024 6:45:00 PM | |
| | <u>Advice</u> | | Amount |
| | ECHO 2D | Total | 1500 |
| | | D/C | |
| | | Net | 1500 |
| | | | |

C/O: Health city lab

PAID



Uttara EPZ Medical Centre

Uttara Export Processing Zone

Shangalshi, Nilphamari.

Tel: +88-02-589960330

3730



Money Receipt

Sl. No. _____

Date 8-2-24

Amount 100

Account Code No. ECC

Name Imran

ID No. 2452-Ventura Age 32 Sex: M/F

Refd. by Dr./Prof. Dr: Raysul Kabir (MBBS)

| INVESTIGATIONS | CHARGES |
|--------------------------|---------|
| ECC — | 100 |
| TOTAL | 100 |
| Delivery on..... at..... | |

laiba
Signature

R

ID: / Name: MD. MIRAN / Age: 38 years / Male

Chest PA

19-02-21 5:20:07 PM

85.7%

Ref. by: ASST. PROF. DR. ABUL KALAM AZAD MBBCh, FCP(S) (M)

MT

Brain & Mind Consultation & Diagnostic Centre Dhaka, Jail Road, Rangpur. Mob: 01719244564



রংপুর হেলথ সিটি স্পেশালাইজড হসপিটাল এন্ড ডায়াগনোস্টিক সেন্টার
Rangpur Health City Specialized Hospital & Diagnostic Center

কাকলী লেন, আটতলা মসজিদের
উত্তর পার্শ্ব, ধাপ, রংপুর।
হেল্প লাইনঃ ০১৭১৭-৩০২০০২
ই-মেইলঃ rhcspdc@gmail.com

Haematology Test Report

Estimation are carried out by SYSMEX Automated Haematology Analyzer (Model XN- 550) & varified manually




| | |
|--|----------------------------|
| Patient ID: 20240210-016 | Lab ID: 20240210-0016 |
| Patient Name: MD IMRAN | Age: 38, Sex: MALE |
| Ref By: Assistant Prof. Dr. Md. Abul Kalam Azad (Tutul) MBBS, FCPS (Medicine). | Date Delivered: 10-02-2024 |

| Investigation | Result | Unit | Reference Range |
|---------------------------|--------|-------------|----------------------------|
| Haematology | | | |
| Haemoglobin | 12.0 | g/dL | M: 13 - 18, F: 11.7 - 16.5 |
| ESR (Westergren Method) | 20 | mm/1st Hour | Male: <10, Female: <15 |
| WBC Panel | | | |
| Total WBC Count | 10,200 | /cmm | 4000 - 11000/cmm |
| Differential Count | | | |
| Neutrophils | 63 | % | 40 - 75 % |
| Lymphocytes | 31 | % | 20 - 50 % |
| Monocytes | 02 | % | 02- 10 % |
| Eosinophils | 03 | % | 01-06% |
| Basophils | 00 | % | 0-01% |


Md. Rakibuzzaman

Medical Technologist
Sr. Lab Incharge
Rangpur Health City Specialized Hospital
& Diagnostic Center


DR. BEAUTY KHATUN
MBBS,BCS(H),M.PHIL (Biochemistry)
Ex- Assistant Professor
Department of Biochemistry
Prime Medical College, Rangpur
BMDC Reg: A-69439

স্বাস্থ্যের মধ্যে সু-চিকিৎসা প্রদানে আমরা অধিকার বদ্ধ



রংপুর হেল্থ সিটি স্পেশালাইজড হসপিটাল এন্ড ডায়াগনোস্টিক সেন্টার
Rangpur Health City Specialized Hospital & Diagnostic Center

কাকলী লেন, আটতলা মসজিদের
উত্তর পার্শে, ধাপ, রংপুর।
ফোন লাইনঃ ০১৭১৭-৩০২০০২
ই-মেইলঃ rhcspdc@gmail.com

Biochemical Test Report

Test carried out by Automated Biochemistry Analyzer "Humalyzer 4000" Germany



| | |
|--|----------------------------|
| Patient ID: 20240210-016 | Lab ID: 20240210-0016 |
| Patient Name: MD IMRAN | Age: 38, Sex: MALE |
| Ref By: Assistant Prof. Dr. Md. Abul Kalam Azad (Tutul) MBBS, FCPS (Medicine). | Date Delivered: 10-02-2024 |

| Investigation | Result | Unit | Reference Range |
|--------------------|--------|--------|--|
| Biochemical | | | |
| Random Blood Sugar | 5.7 | mmol/L | Normal : <7.8 Impaired : 7.8-10.1 Diabetic : >10.1 |
| CUS | Nil | | |
| Serum Creatinine | 1.02 | mg /dl | Male: 0.70-1.30 mg /dl Female: 0.50-1.10 mg/dl |

Md. Rakibuzzaman

Medical Technologist

Sr. Lab Incharge

Rangpur Health City Specialized Hospital
& Diagnostic Center

DR. BEAUTY KHATUN

MBBS, BCS(H), M. PHIL (Biochemistry)

Ex- Assistant Professor

Department of Biochemistry

Prime Medical College, Rangpur

BMDC Reg: A-69439



স্বাস্থ্যের মধ্যে সু-চিকিৎসা প্রদানে আমরা অসিকার বদ্ধ



রংপুর হেল্থ সিটি স্পেশালাইজড হসপিটাল এন্ড ডায়াগনোস্টিক সেন্টার
Rangpur Health City Specialized Hospital & Diagnostic Center

কাকলী লেন, আটতলা মসজিদের
উত্তর পার্শে, ধাপ, রংপুর।
হেল্প লাইনঃ ০১৭১৭-৩০২০০২
ই-মেইলঃ rhcspdc@gmail.com


Immunology Test Report




| | |
|--|----------------------------|
| Patient ID: 20240210-016 | Lab ID: 20240210-0016 |
| Patient Name: MD IMRAN | Age: 38, Sex: MALE |
| Ref By: Assistant Prof. Dr. Md. Abul Kalam Azad (Tutul) MBBS, FCPS (Medicine). | Date Delivered: 10-02-2024 |

| Investigation | Result | Unit | Reference Range |
|---------------|--------|-------|--|
| Immunology | | | |
| Troponin-I | 0.125 | ng/ml | Adults : 0.000 – 0.300 High Risk : 0.3 – 1.2 AMI : 1.2 and Above |

Rangpur Health City Specialized
Hospital & Diagnostic Center


Md. Rakibuzzaman
Medical Technologist
Sr. Lab Incharge
Rangpur Health City Specialized Hospital
& Diagnostic Center


DR. BEAUTY KHATUN
MBBS, BCS(H), M. PHIL (Biochemistry)
Ex- Assistant Professor
Department of Biochemistry
Prime Medical College, Rangpur
BMDC Reg: A-69439

স্বাস্থ্যের মধ্যে সু-চিকিৎসা প্রদানে আমরা অসিকার বদ্ধ



রংপুর হেলথ সিটি স্পেশালাইজড হসপিটাল এন্ড ডায়াগনোস্টিক সেন্টার
Rangpur Health City Specialized Hospital & Diagnostic Center

কাকলী লেন, আটতলা মসজিদের
উত্তর পার্শে, ধাপ, রংপুর।
হেল্প লাইনঃ ০১৭১৭-৩০২০০২
ই-মেইলঃ rhcspdc@gmail.com

Pathology Test Report



| | |
|--|----------------------------|
| Patient ID: 20240210-016 | Lab ID: 20240210-0016 |
| Patient Name: MD IMRAN | Age: 38, Sex: MALE |
| Ref By: Assistant Prof. Dr. Md. Abul Kalam Azad (Tutul) MBBS, FCPS (Medicine). | Date Delivered: 10-02-2024 |

PHYSICAL EXAMINATION

Quantity : Sufficient
Colour : Straw
Appearance : Clear
Sediment : Absent
Specific Gravity : Not Done

CHEMICAL EXAMINATION

Reaction : Acidic
Albumin : Trace
Sugar : Nil
Excess phosphate : Nil

ON REQUEST

Bile Salts : Not Done
Bile Pigments : Not Done
Ketones : Not Done
Urobilinogen : Not Done
Bacteria : Nil

MICROSCOPIC EXAMINATION

CELLS /HPF :
RBC : Nil
Pus Cells : 0-2
Epithelial Cells : 0-2
Bacteria : Nil

CASTS /LPF

RBC : Nil
WBC : Not Done
Epithelial : Nil
Granular : Nil
Hyaline : Nil

CRYSTALS & OTHERS

Urates : Nil
Uric Acid : Nil
Cal. Oxalate : Nil
Amor. Phos : Nil
Triple. Phos : Nil
Candida : Nil

Md. Rakibuzzaman

Medical Technologist
Sr. Lab Incharge

Rangpur Health City Specialized Hospital
& Diagnostic Center

DR. BEAUTY KHATUN

MBBS,BCS(H),M.PHIL (Biochemistry)

Ex- Assistant Professor

Department of Biochemistry

Prime Medical College, Rangpur

BMDC Reg: A-69439

সাধুত্রে মধুত্রে সু-চিকিৎসা প্রদানে আমরা অঙ্গিকার বদ্ধ



রংপুর হেল্থ সিটি স্পেশালাইজড হসপিটাল এন্ড ডায়াগনোস্টিক সেন্টার
Rangpur Health City Specialized Hospital & Diagnostic Center

কাকদী লেন, আটতলা মসজিদের
উত্তর পার্শে, ধাপ, রংপুর।
হেল্প লাইনঃ ০১৭১৭-৩০২০০২
ই-মেইলঃ rhcspdc@gmail.com

Ultrasonogram Report

| | | | |
|-----------------|---|------|----------|
| Name of Patient | Mr. Imran | Age | 38 Yrs |
| Referred by | Asst.Prof.Dr.Abul Kalam Azad(Tutul),MBBS, FCPS(M) | | |
| USG of | Whole abdomen | Date | 10-02-24 |

- Liver** : Normal in size, shape, position & hepatic parenchymal echotexture. No abnormal focal or diffuse lesion are seen. Portal & hepatic veins are not dilated.
- Biliary Channels** : The intra-hepatic & extra hepatic biliary channels including CBD are not dilated. No calculi in CBD.
- Gallbladder** : Normal in size, shape & Position. Its lumen is anechoic and free of sludge or stones. Its wall thickness is within normal limits.
- Pancreas** : Normal in size, shape & echogenicity. Pancreatic duct is not dilated.
- Spleen** : Normal in size, shape & echogenicity. Splenic vein is not dilated.
- Kidneys** : Both Kidneys are normal in size, shape & position with well defined cortex & medulla. No pelvicalyceal dilatation of both kidneys. No calculus seen within them.
- Urinary bladder** : Well filled & border is regular. Wall thickness is normal. No calculus is noted.
- Prostate** : Normal in size. It shows homogenous echotexture with smooth and intact capsule.

Comment : Normal Study.

10-100-24

Dr. Shah Md. Rakib Uz Zaman
MBBS, CCU(Dhaka)
Diploma in Medical Ultrasound(BTEB)
PGT (Radiology & Imaging)
Advanced training in anomaly scan,
Color Doppler & Vascular ultrasound
Clinical sonologist

সাধের মধ্যে সু-চিকিৎসা প্রদানে আমরা অস্বিকার বদ্ধ

RANGPUR HEALTH CITY SPECIALIZED HOSPITAL

Name: IMRAN
ID: 20240210-180449-D534
Gender: Unknown

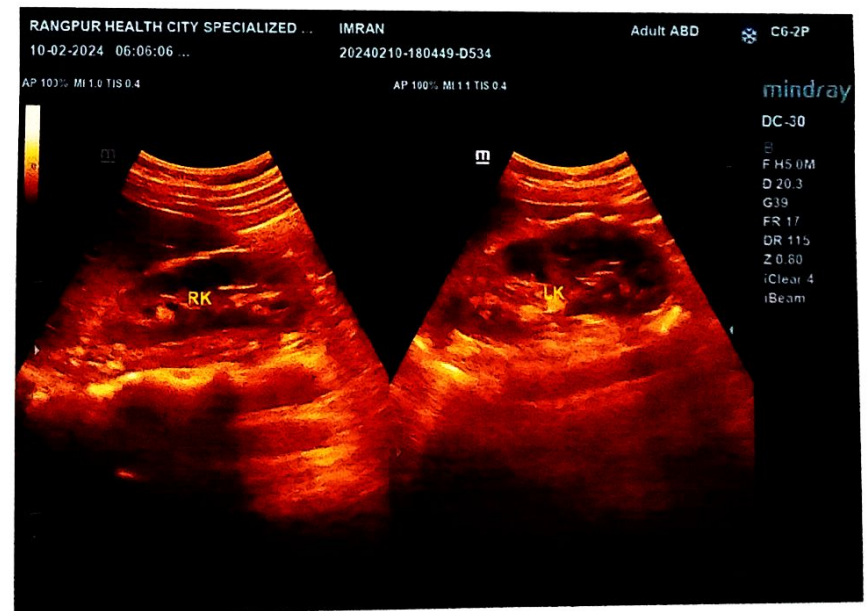
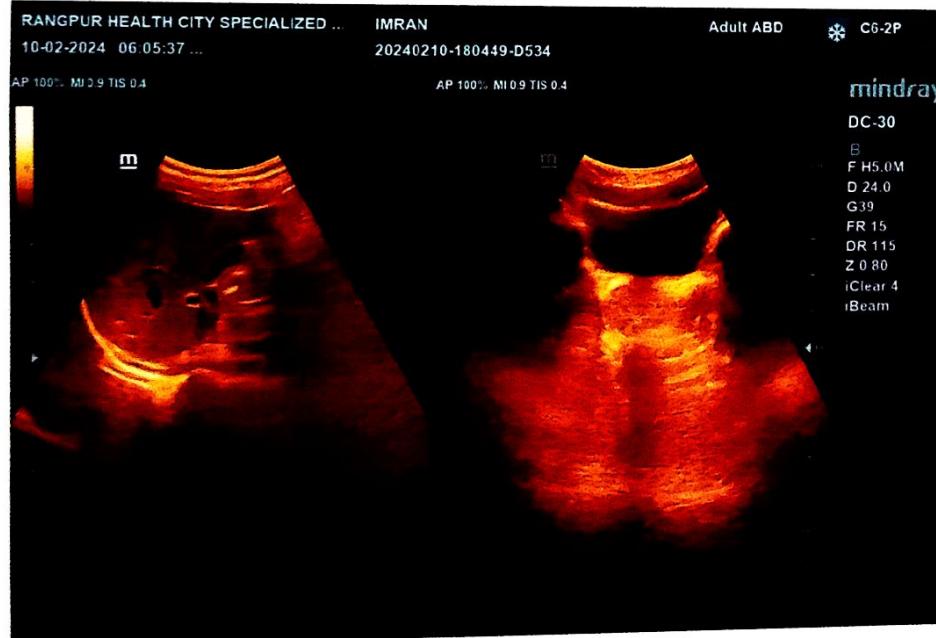Telephone:
Fax:
Website:



Adult ABD
Exam Date: 10/02/2024
Equipment Used: MINDRAY DC-30

Abdomen

Ultrasound Image





হেমা ডিজিটাল ডায়াগনস্টিক সেন্টার

HEMA DIGITAL DIAGNOSTIC CENTRE

বরলিপি ম্যানসন, ৬৮, ধাপ সিটি বাজার, ক্যান্ট রোড, রংপুর (চেকপোস্ট হতে ২০০ গজ পূর্ব দিকে), মোবাইল: ০১৭০৮-৯৬৬২২৬

CARDIAC TEST REPORT

| | | | | |
|-----------------|---|-----|---------|-----------|
| Name of Patient | Md. Emran | Age | 38 Year | 10-Feb-24 |
| Refd by : | Asst. Prof.Dr.Md.Abul Kalam Azad(Tutul),MBBS,BCS(H),FCPS(M) | | | |
| Test Name: | Echo Cardiography 2D | | | |

Procedure: 2D & M mode

| | | Normal | | | Normal |
|---------|--------|-----------------------|--|--------|----------|
| IVSt | 10 | 06-11 mm | | EPSS | <9 mm |
| LVPWt | 07 | 06-11 mm | | AOD | 28 |
| LVIDd | 47 | 34-55 mm | | LAD | 35 |
| LVIDs | 30 | 22-38mm | | ACS | 22 |
| LVEF | 66% | Mentioned Below | | LA/AO | 1.0 |
| FS | 36% | 28-40% | | RVA Wt | 15-26 mm |
| PA | Normal | 15.35 mm | | TAPSE | <5 mm |
| MV area | Normal | > 2.5 cm ² | | | > 17mm |

LVEF= (Normal male-52-72%, Female -54-72%)

IMAGING:

PERICARIUM : Normal. No pericardial effusion
LV WALL MOTION : No RWMA
VALVES : Normal
CHAMBERS : Normal
IAS : Intact.
IVS : Intact.
THROMBUS & VEGETATION: Absent.

COMMENT:

- ❖ No RWMA
- ❖ Good LV systolic function (EF-66%)
- ❖ No Pericardial effusion

Adv:

Assist. Prof. Dr. Md. Rezaul Alam

MBBS(DMC); BCS (H); D-Card (BSMMU) ,
PhD, FIACC(Cardiology) India
Assistant Prof. of cardiology
M.Abdur Rahim Medical College,Dinajpur

Handwritten signature and date: 10/2/24

HEMA DIGITAL DIAGNOSTIC CENTER

Name: imran
ID: 1385
Age: 38 Years
Gender: Male

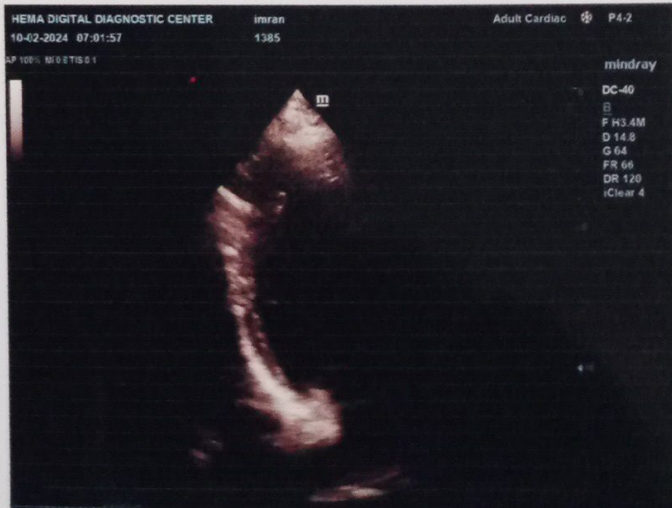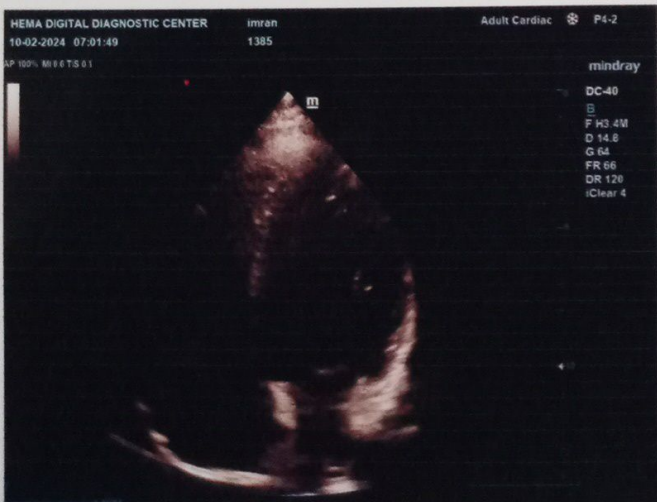
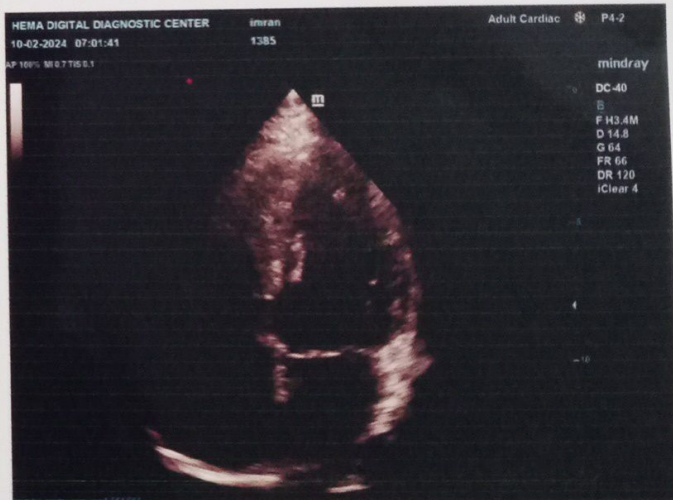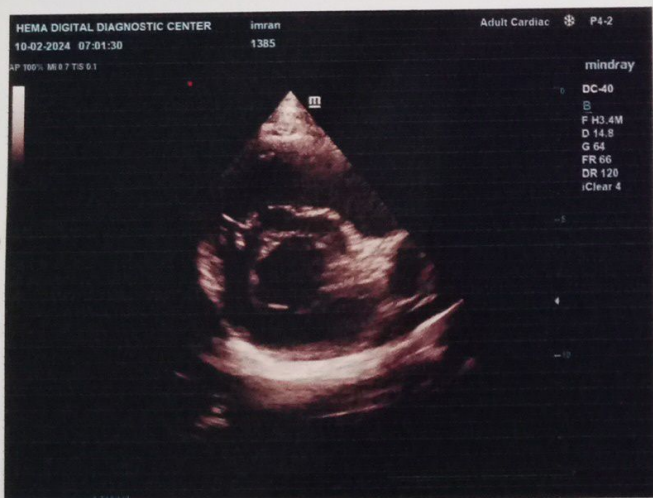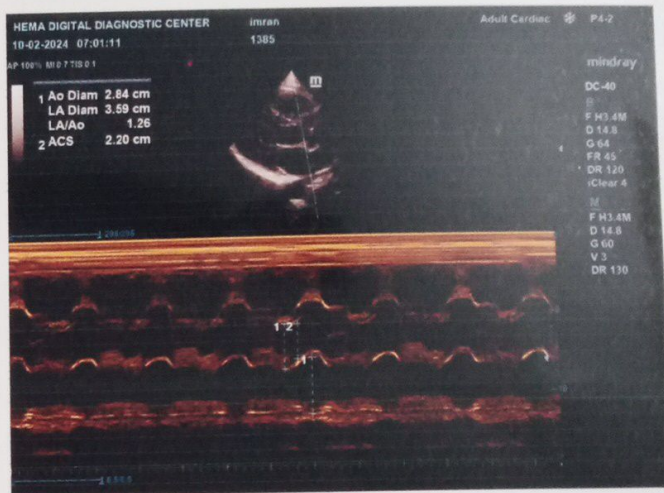
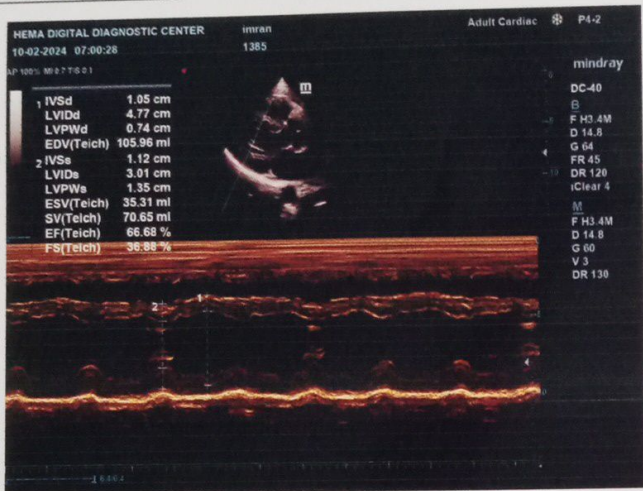
68, Dhap City Bazar, Cant. Road, Rangpur.
Telephone: 01711907192
Fax:
Website:



Adult Cardiac
Exam Date: 10/02/2024
Equipment Used: Mindray DC-40

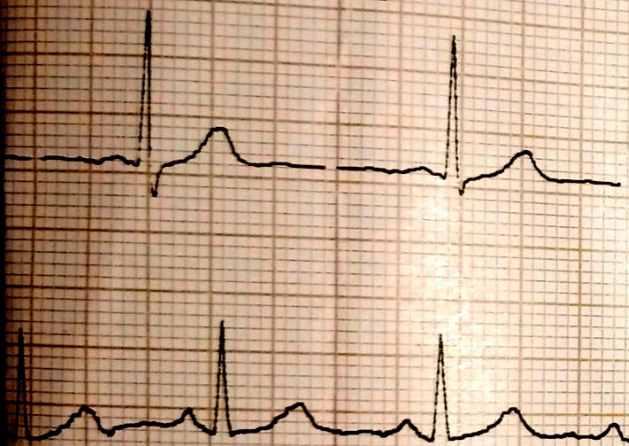
Cardiology

Ultrasound Image



V5

V6



**** Borderline Normal ****

401: Short P-R Interval

HR : 88bpm

R-R: 678ms

P-R: 119ms

QRS: 99ms

QT : 363ms

QTc: 440

AXIS: 46deg

RV5: 1.33mV

SV1: 0.70mV

R+S: 2.03mV

[MINNESOTA CODE]

6-5-0

FCP-7101-V03-02-S1

12

Unconfirmed report :

Reviewed by

FCP-7101-V03-02-S1