



BIOCHEMISTRY REPORT



Invoice No : 537A88211387

Invoice Date: 22-Aug-24

Report Code : 202421371

Patient Name : SANJU HOSSAIN

Age : 32 Y

Gender : Male

Referred By : Dr. Miah Mohammad Rubel ; ; MBBS, (DMC) ; MCPS , FCPS (Medi), MD (Gastro)

Sample : BLOOD

Test Name : ALT (SGPT);

Estimations are carried out by SPHERA-EDIF-ITALY Full Auto Clinical Chemistry Analyzer.

| Test | Result | Reference Value |
|------------|--------|--|
| ALT (SGPT) | 54 U/L | Male : ≤ 42 U/L Female : ≤ 32 U/L |

NEWTON KUMAR BARMAN

B.Sc(Hon's)in MT(Lab),RU

Medical Technologist

Labzone Diagnostic, Rangpur

Print by & Date : Newton :: 22-Aug-24 6:38:27 PM

Asst. Prof. Dr. Fahmida Parvin Lubna

MBBS;BCS;DMU;CCD

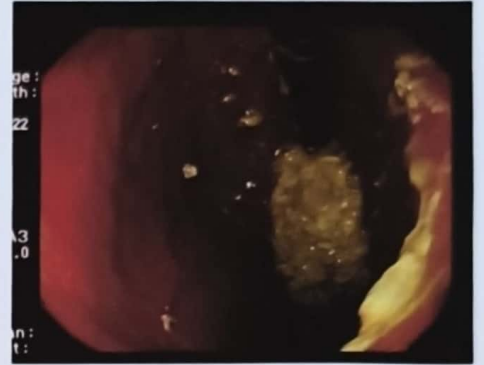
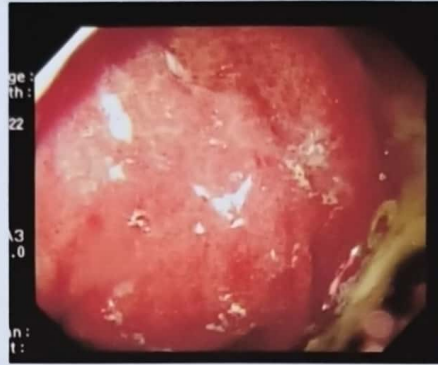
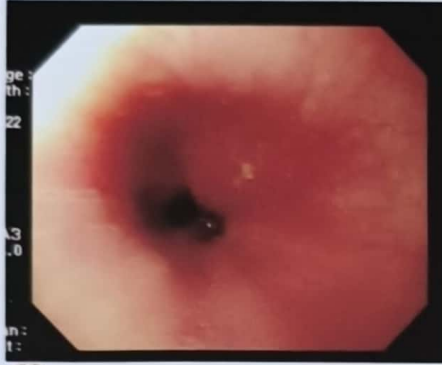
M-Phil(Biochemistry)

Department of Biochemistry

Rangpur Medical College, Rangpur

| | | | |
|--------------|---|------------|-----------|
| Identity No. | 21371 | Visit Date | 22-Aug-24 |
| Patient Name | SANJU HOSSAIN | Age / Sex | 32 / Male |
| History | N/A | Instrument | N/A |
| Referrer | DR. MIAH MOHAMMAD RUBEL, MBBS, FCPS(MED), M Bed | | OPD |

ENDOSCOPIC PROCEDURE REPORT



Procedure : UPPER G. I. TRACT ENDOSCOPY

Indication :

Medication :

FINDINGS :

Oesophagus:- lumen, mucosa, vascular pattern and peristalsis appear normal. No varix is seen.


Stomach:- Multiple erythema, erosions and ulcers are seen in the fundus, body and antrum. No fundal varix is seen.

Duodenum:- A large ulcer is seen in the bulb. Post bulbar area upto 2nd part appear normal.

Biopsy:- Not taken.

COMMENTS :

Peptic Ulcer Disease



Dr Miah Mohammad Rubel
 MBBS(DMC), BCS(Health)
 FCPS(Medicine), MD(Gastro)
 Consultant, Medicine

